



This case report demonstrates the successful use of PURINA® PRO PLAN® VETERINARY DIETS Canine HA Hypoallergenic formula in the management of a dog with FRE.

Exclusion Diet and Food Responsive Enteropathy (FRE)

Dr Oliver Garden

Royal Veterinary College,
Hatfield, UK

History

Ben is an 11 year old, male neutered Golden Retriever, who was presented for further investigation of chronic lethargy, episodes of excessive swallowing and borborygmi, and episodic small intestinal diarrhoea

Clinical Examination and Diagnostic Approach

Physical examination revealed a subdued but responsive patient in good body condition. Notable physical findings included a grade II/VI left apical systolic cardiac murmur, pronounced respiratory sinus arrhythmia and loud borborygmi. Other physical findings were within normal limits, including rectal, otoscopic and fundic examinations. Mean non-invasive systolic blood pressure was 145 mmHg.

Tests performed to assess Ben's clinical status included a complete blood cell count (CBC), serum biochemical profile, routine urinalysis of a free

catch sample, serum folate and cobalamin assays, faecal flotation, thoracic radiography and abdominal ultrasonography. Further tests included electrocardiography and echocardiography, a fluoroscopic swallowing study, an ACTH stimulation test and gastroduodenoscopy.

The baseline CBC, serum biochemical profile, assays of serum folate and cobalamin, and routine urinalysis were unremarkable. Faecal flotation was negative. Thoracic radiographs showed some indrawing of the dorsal tracheal ligament in the caudal cervical trachea, but was otherwise unremarkable. Abdominal ultrasonography was within normal limits, with no sonographic lesions of the small intestine or associated viscera. A fluoroscopic swallowing study confirmed normal cervical and oesophageal phases for both liquid and solid material. An ACTH stimulation test demonstrated adequate adrenal reserve, providing no support for the remote possibility of glucocorticoid-deficient hypoadrenocorticism. An ECG confirmed respiratory sinus arrhythmia, while echocardiography revealed significant mitral regurgitation, but no other valvular or myocardial lesions.



Ben at 11 years of age.

PURINA®
PRO PLAN®
VETERINARY
DIETS

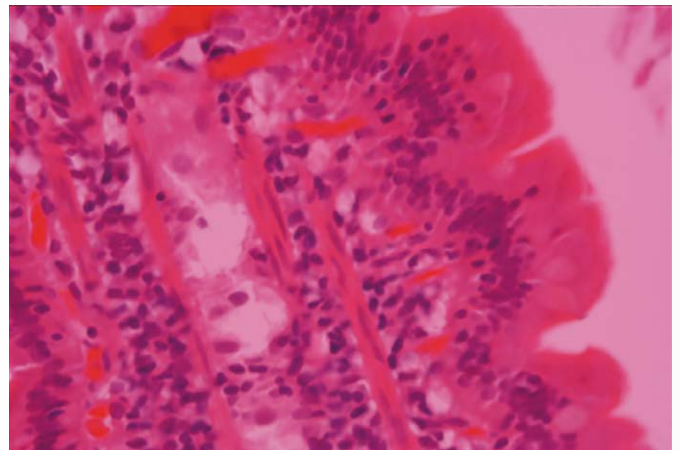
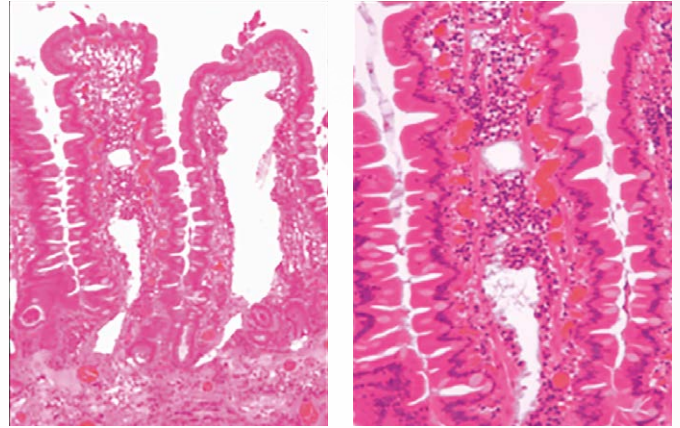
Gastroduodenoscopy revealed irregularity and increased friability of the duodenum, but no gross abnormalities of the stomach or distal oesophagus. Histopathological review of endoscopic biopsies revealed moderate lymphoplasmacytic infiltration of the duodenum and lacteal dilatation; there were no significant histopathological lesions of the stomach.

Differential Diagnoses

Clinicopathological findings suggested a gastrointestinal cause of the repeated swallowing episodes, borborygmi and diarrhoea: differential diagnoses included food-responsive enteropathy (FRE) and inflammatory bowel disease (IBD). Malabsorption secondary to primary intestinal disease was thought to account for gaseous distension of the bowel wall, leading to nausea, discomfort and the swallowing episodes characteristic of this case.

PURINA® PRO PLAN® VETERINARY DIETS Canine HA Hypoallergenic formula was fed as an exclusion diet. Clinical signs abated within seven days, suggesting a diagnosis of FRE. Ben no longer had frequent 'swallowing' episodes, the borborygmi disappeared, and the diarrhoea resolved.

Now, more than one year later, Ben continues to show no gastrointestinal signs. He is still fed Canine HA Hypoallergenic formula, now with occasional 'treats' of boiled fish.



Sections of duodenum depicting mononuclear inflammation and lacteal dilation (x10, x20, x40).

Nestlé Purina would like to thank Dr Oliver Garden at the Royal Veterinary College, UK for providing the details and images of this case and Dr Carolina Mancho Alonso for having prepared the photomicrographs.