




## Haemorrhagic cystitis in a female cat

Dr. Jérôme Seguela, veterinary practitioner in Biarritz



Candy is a spayed Domestic cat aged 4 years; she was brought in for examination as she had been suffering from dysuria, stranguria, periuria and haematuria for 3 days.

Candy was up to date with her vaccinations and regularly wormed. She had been fed *ad lib.* with a widely-used

supermarket brand of dry cat food. Candy had access to outdoors. There was no history of previous disease.

### Clinical examination

Candy had a normal body temperature, weighed 4.3 kg, with an ideal body condition score (BCS 3/5). Her vital parameters lay within normal limits. She showed a degree of discomfort on abdominal palpation in the caudal region. The examination of the ear/nose/throat region, including the buccal cavity and the peripheral lymph nodes, were normal.

### Supplementary examinations

#### a. Blood tests

Baseline blood chemistry tests (Urea, creatinine, ALP, ALT, TP, Albumin, Glucose, Ca, PHOS) and a haematological examination revealed no major abnormalities.

#### b. Urinalysis

The urinalysis revealed a urinary specific gravity of 1.030, a pH of 6 and a positive peroxidase activity; the findings for the other reagents on the urine test strip were normal or negative. An examination of the urine sediment revealed haematuria without crystalluria. Bacteriological examination of the urine gave a negative result.

#### c. Radiology and ultrasound report

The radiographs of the urinary tract revealed small, round, slightly radiopaque areas in the bladder, with a diameter of a few millimetres. The radiological appearance of the kidneys was normal. The ultrasound scan of the bladder showed a wall with a moderately irregular and considerably increased thickness, suggesting the presence of a marked widespread inflammatory condition. An assessment of the contents of the bladder revealed the presence of hyperechogenic elements in suspension and in the region distal to the bladder neck.

### Diagnosis

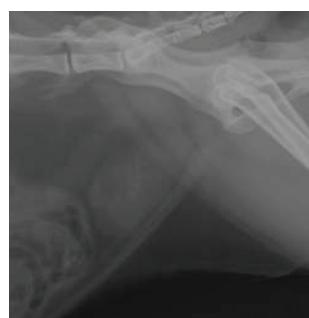Candy presented clinical signs of feline lower urinary tract disease (FLUTD). The clinical, radiological and ultrasonographic findings were suggestive of haemorrhagic cystitis.

The images of hyperechogenic elements associated with an ultrasound attenuation distally may be attributable to the presence of blood clots and/or uroliths. In fact, the lack of crystalluria is not sufficient to rule out the presence of uroliths as crystalluria is not systematically present in cases of urolithiasis (Sturgess *et al.*, 2001).

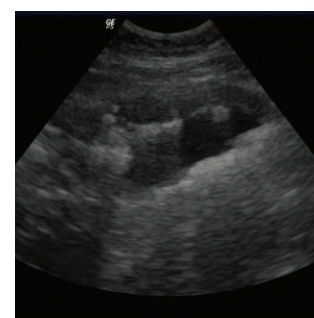On the epidemiological level, cystitis is the first cause of FLUTD before urolithiasis; then urolithiasis is the second cause with struvite and calcium oxalate uroliths accounting for the majority of calculi in France (Vedrenne *et al.*, 2003).

The urine test strip does not measure the pH with a high degree of precision but rather gives a variation of 1 unit more or less with respect to the value measured using a pH meter (Wamsley and Alleman, 2007). It is therefore difficult to determine the potential nature of the mineralized elements.

The clinical signs associated with the ultrasound and radiograph suggest the presence of haemorrhagic cystitis perhaps accompanied by the presence of uroliths.



Radiograph of Candy at Do



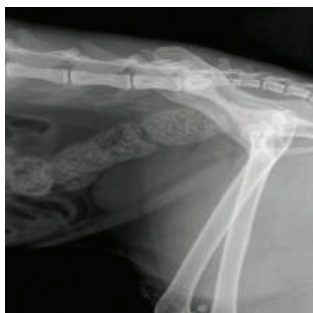Ultrasound scan of Candy's bladder at Do

### Management and Follow-up

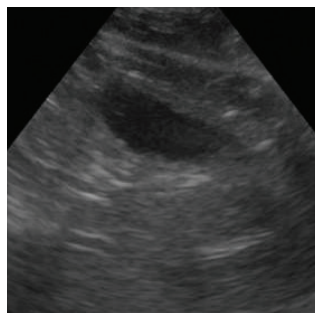A non-steroidal anti-inflammatory treatment (meloxicam: 0.1mg/kg/day, orally, for 10 days) was initiated to relieve the pain suffered by Candy.

Dietary management with the cat food PURINA VETERINARY DIETS UR St/Ox dry was initiated. This is recommended both for the dissolution of struvite uroliths and the nutritional

management of idiopathic cystitis. In this case, the dry form was chosen to avoid changing Candy's dietary habits.



*Radiograph of Candy after one month*



*Ultrasound image of Candy's bladder after one month*

The clinical signs disappeared rapidly after 3 days. At the check-up after 1 month, Candy's general clinical examination revealed no abnormalities. The radiographs and ultrasound scan no longer showed radiodense or hyperechogenic images. This progress was compatible with the initial presence of struvite uroliths, which are the only kind that can be dissolved medically *in situ*. Follow-up biological urinalysis and blood tests, together with medical imaging check-ups at 2 months and 4 months remained normal.

### Discussion and conclusion

In therapeutic terms, the nutritional management of cats with urolithiasis has a dual objective:

To reduce urine saturation by:

- Increasing urinary output: to do this, the cat's water intake must be increased by giving wet food, increasing in the number of water bowls, using water fountains, or feeding a diet that stimulates water intake.
- Reducing urinary stasis: there should be one more litter tray than the number of cats to favour urination.
- Limiting metabolic waste: to do this, high-quality foods should be favoured.
- Choosing foods with low RSS and APR, parameters that allow the diet to reduce the urinary saturation and modify the dynamics of urolith formation.

To stabilize the urine pH by:

- Dividing up meals: cats fed *ad libitum*. present more stable urinary pH across the day (Lewis et Morris, 1984).

- Stabilizing the feed formula by using the same, high-quality food.
- Acidifying the urine (for struvite uroliths only).

The painful inflamed bladder, the origin of the clinical signs of FLUTD, was also managed in our case with the aid of a non-steroidal anti-inflammatory drug. Urinary anti-spasmodics (phloroglucinol) may also be considered. The aim was to obtain a rapid clinical improvement, the disappearance of the clinical signs, and comfort for the animal.

On average, it takes 30 days to dissolve uroliths in the lower urinary tract (Houston *et al.*, 2004; Osborne *et al.*, 1990). The check-up carried out at 1 month in our case confirmed this.

If diet is well controlled, the relapse rate is low (Osborne *et al.*, 1990): a 4-month follow-up confirmed that this cat, in the medium term, remained controlled.

The diet PURINA VETERINARY DIETS Feline UR St/Ox may be recommended for long term use: by aiming at a urinary pH of 6.2 and favouring the production of urine that is undersaturated for struvite crystals and metastable for calcium oxalate crystals, it helps to maintain a urinary environment that prevents the formation of struvite and calcium oxalate uroliths.

---

### Further Reading

- Houston DM, Rinkardt NE, Hilton J. Evaluation of a commercial diet in the dissolution of feline struvite bladder uroliths. *Vet Ther* 2004 ;**5** :197-201.
  - Lewis LD, Morris ML Jr. Treatment and prevention of feline struvite urolithiasis. *Vet Clin North Am Small Anim Pract* 1984 ;**14**(3) :649-660.
  - Osborne CA, Lulich JP, Kruger JM et coll. Medical dissolution of feline struvite urocystoliths. *J Am Vet Med Assoc* 1990 ;**196** :1053-1063.
  - Sturgess C, Hesford A, Owen H, et coll. An investigation into the effects of storage on the diagnosis of crystalluria in cats. *J Feline Med Surg* 2001 ;**3** :81-85.
  - Vedrenne N, Cotard JP, Paragon B. L'urolithiase féline : actualités épidémiologiques. *Point Vet* 2003 ;**232** :44-48.
  - Wamsley et Alleman, Complete urinalysis In: *BSAVA Manual of Canine and Feline Nephrology and Urology* 2007 ; 87-116.
-