



This case report demonstrates the benefits of PURINA® PRO PLAN® VETERINARY DIETS Feline UR St/Ox Urinary in the prevention of recurrent calcium oxalate uroliths in a cat

Prevention of recurrent calcium oxalate uroliths using Feline UR St/Ox Urinary

Dr Aurélie Baril

(Clinical Research Assistant), CHUVA, ENVA
Avenue du général de Gaulle, 94700
Maisons-Alfort, France



Balzac, a 5 year old castrated male domestic cat, presented with a 3 year history of recurrent urinary problems (pollakiuria, stranguria, haematuria, urinary soiling and pruritus in the perineal region). The frequency of these symptoms had increased over time.

The symptoms normally subsided within a few days of treatment with meloxicam (Meloxoral™) and phloroglucinol (Spasmoglucinol™). The owner reported no obstructive episodes.

The most recent episode of symptoms three months previously had not resolved with alpha S1-casein (Zylkène™) and homoeopathic treatment (Uricystil™) and had not responded to a struvite dissolving diet (Royal Canin Urinary S/O HD).

No additional examinations were performed. The haematuria had become worse over time.

Balzac had been with his owners since the age of two months. For the past three years, he had lived in a detached house with access to a garden. His vaccinations were not up-to-date, having lapsed in 2012. He was regularly wormed and treated for external parasites (fipronil spot-on). He had not received any treatment recently.

Balzac was being fed ad lib with a dry food, Royal Canin Urinary S/O. He was also receiving occasional table scraps. He had ad lib tap water and access to two litter trays.

His owners described Balzac as naturally timid and prone to anxiety.

Balzac also had occasional (uninvestigated) episodes of coughing/dyspnoea, which stopped within five days of treatment with cephalexin (Therios™, 15 mg/kg). He had not shown these symptoms for several weeks.

Clinical examination

The general clinical examination did not identify any particular abnormalities. Balzac's general condition was good. He weighed 4.6 kg (body condition score estimated at 5/9). His temperature (37.6 °C) and hydration status were normal. The mucosa were pink and moist, heart and lung auscultation was unremarkable (HR 180 bpm, femoral pulse clear and synchronous with the heart beat, RR 30 pm).

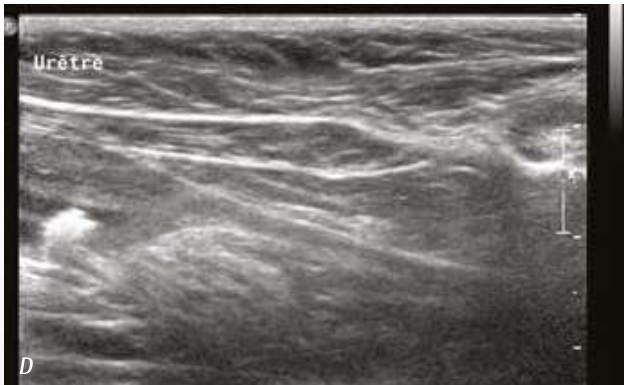
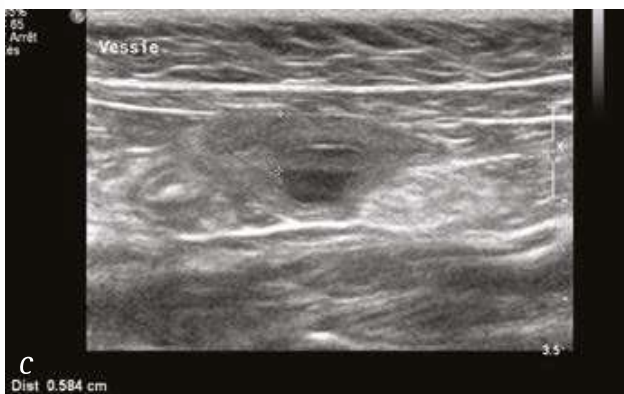
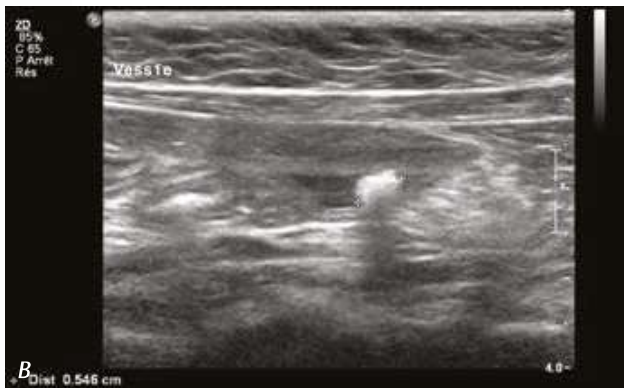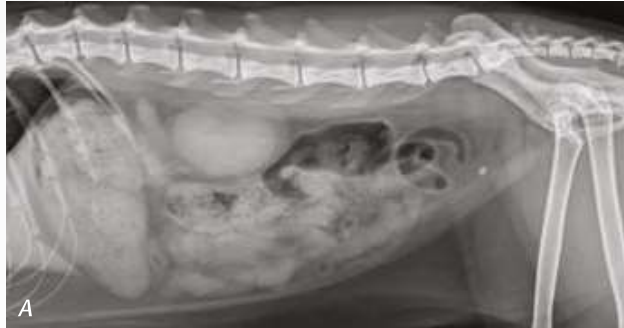The abdomen was relaxed and not painful on palpation. The bladder was small. Palpation caused the cat to urinate; there were no macroscopic signs of haematuria. The perineal region was clean and non-inflamed.

Additional examinations and diagnosis

The differential diagnosis of lower urinary tract disorder in the cat includes urolith disease (calculi composed of struvite, calcium oxalate, urate, etc.), idiopathic cystitis, urinary infection (generally secondary in the cat) and, less probable, a tumour (transitional cell carcinoma of the bladder, lymphoma, etc.).

Abdominal radiography revealed a radio-opaque object, about 4 mm long, in the bladder, compatible with the presence of a bladder calculus. Urinary tract ultrasound confirmed the presence of a 5 mm bladder calculus. There were associated signs of cystitis (wall thickness 6 mm). The kidneys were of normal appearance.

PURINA
PRO PLAN
VETERINARY
DIETS



Urinalysis (cystocentesis) identified no significant abnormalities (urine density 1.032, pH 6, blood +++++, protein +, no urinary sediment on macroscopic or microscopic examination, no crystalluria, urine culture negative). Similarly, blood tests (biochemistry and haematology) found no significant abnormalities.

Details of biochemical and haematological parameters assessed on Balzac's admission

PARAMETERS	VALUE ON DO	REFERENCE RANGE
Urea (mmol/l)	6.8	3.4-11.8
Creatinine (µmol/l)	115	0-177
ALP (IU/l)	39	50-105
ALT (IU/l)	64	0-175
Total protein (g/l)	66	50-70
Albumin (g/l)	30	25-40
Glucose (mmol/l)	5.88	4.44-6.66
Total calcium (mmol/l)	2.38	2.0-2.63
Phosphorus (mmol/l)	1.42	0.97-1.94

PARAMETERS	VALUE ON DO	REFERENCE RANGE
Haematocrit (%)	32.3	27-51
Haemoglobin (g/l)	11.5	9.7-17.2
Red blood cells (x 10 ¹² /l)	8.75	6.1-12
MCV (fl)	36.9	31.4-52.5
MCH (pg)	13.1	11.4-17.2
MCHC (g/l)	356	308-395
Reticulocytes (x10 ⁹ /l)	1.42	0.15-1.06
Platelets (x10 ⁹ /l)	255	180-550
Leucocytes (x10 ⁹ /l)	7.53	3.5-25
Neutrophils (x10 ⁹ /l)	5.55	11.8-12.11
Eosinophils (x10 ⁹ /l)	0.37	0.15-1.9
Basophils (x10 ⁹ /l)	0.01	0-0.1
Lymphocytes (x10 ⁹ /l)	1.35	1.10-10.85
Monocytes (x10 ⁹ /l)	0.25	0.09-1.18
Other cells (x10 ⁹ /l)	x	x

Radiological (A) and ultrasound (B) images of the bladder calculi. Note the associated parietal thickening (C). No associated urethritis (D).

Management and Follow-up

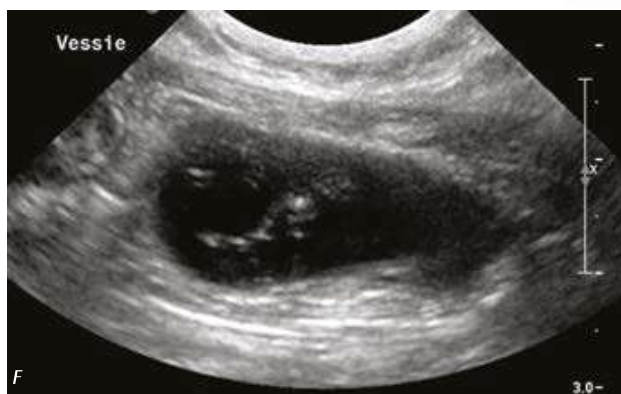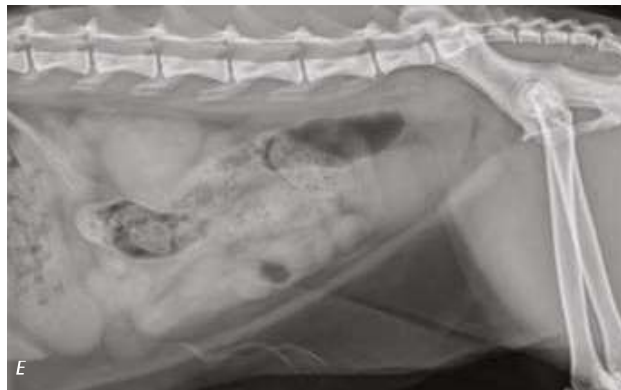In view of the radio-opacity of the calculi, the absence of a response to the previously introduced struvite dissolving diet, and the association of an acid pH urine without crystalluria, a calcium oxalate calculus was strongly suspected. Removal of the calculus by cystotomy was therefore considered, and was subsequently performed. Analysis by infrared spectrometry was performed on this 4x5 mm calculus, which was hard in consistency, with a rough surface and reddish colour. It was composed of 60% calcium oxalate dihydrate and 40% calcium oxalate monohydrate.

Feeding with Feline UR S7/Ox Urinary as a dry diet was initiated in order to prevent a recurrence. The owner was also offered advice on managing the cat's condition (increasing the number of water sources available in the home, changing litter trays daily, minimising environmental changes). In addition, Balzac was given meloxicam (Metacam™, 0.1 mg/kg SID PO) for three consecutive days for post-surgical analgesia.

The two-week post-surgical follow-up showed the cat in good general condition apart from some occasional persistent urinary problems (pollakiuria/haematuria). The owner described dietary compliance as very good (the diet comprised almost all of the cat's food intake, except for occasional scraps of meat). Balzac weighed 4.8 kg, his temperature (38.5 °C) and hydration status were normal, and no abnormalities were found on auscultation of the heart and lungs. Abdominal palpation was not painful. The cystotomy wound was clean and the skin sutures were removed. No additional examinations were performed on account of the cat's young age at surgery.

Urinary muscle relaxants (alfuzosin, XATRAL™, 0.05 mg/kg TID PO and dantrolene, DANTRIUM™, 0.5 mg/kg TID PO) were prescribed for 5 days, resulting in a clinical improvement. Progress was nonetheless deemed very pleasing.

The one-month follow-up was also without concern. The owner reported only a single episode of urinary soiling. The other symptoms (haematuria, stranguria, pollakiuria) had stopped completely. Dietary compliance remained very satisfactory. Balzac was not receiving any other treatment. Clinical examination revealed no abnormalities (T 38.5 °C, HR 180 bpm, RR 42 pm, mucosae pink and moist, abdominal palpation relaxed and not painful). A follow-up urinary tract ultrasound identified only the presence of fine suspended particles in the bladder lumen, with no signs of cystitis, calculi or sediment. Abdominal radiography found no urinary tract abnormalities. Urinalysis (cystocentesis) identified a urine density of 1.050, pH 7.5, protein (++++), and blood (++++). There was no urinary sediment on macroscopic or microscopic examination. Progress was deemed very satisfactory. Feeding with Feline UR S7/Ox Urinary was continued. The owner was reminded about the importance of continuing treatment for external parasites (fipronil).

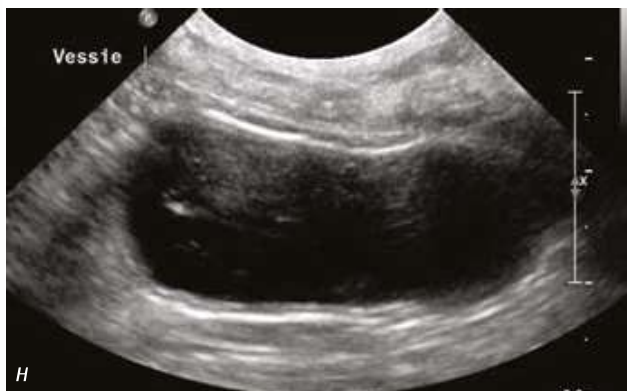
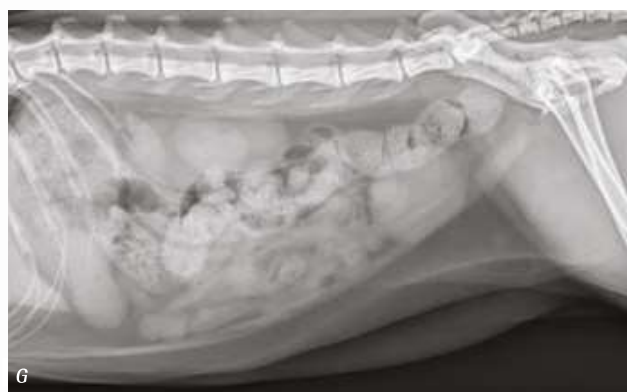
Radiological (E) and ultrasound (F) follow-up of the bladder calculi after 1 month. Note the absence of visible calculi and the presence of fine suspended particles (F).

PURINA
PRO PLAN
VETERINARY
DIETS

The two-month follow-up was also very satisfactory, Balzac was asymptomatic. The owner reported continuing good compliance with the diet. Balzac's general condition was excellent. He weighed 4.5 kg and clinical examination revealed no abnormalities (T 37.9°C, HR 200 bpm, RR 60 pm, mucosae pink and moist, abdominal palpation relaxed and not painful).

No radio-visible calculi were identified in the follow-up radiograph. The follow-up urinary tract ultrasound was similar to the previous one: only a few suspended particles were identified. Urinalysis (cystocentesis) identified a urine density of 1.050, pH 7.5, protein (++++) and blood (++++). Blood tests (biochemistry and haematology) found no significant abnormalities.



Radiological (G) and ultrasound (H) follow-up of the bladder calculi after 2 months. Note the absence of visible calculi and the presence of fine suspended particles (H).

Details of biochemical and haematological parameters assessed two months after Balzac's cystotomy.

PARAMETERS	VALUE ON D60	REFERENCE RANGE
Urea (mmol/l)	8.82	3.4-11.8
Creatinine (mmol/l)	79.5	0-177
ALP (IU/l)	54	50-105
ALT (IU/l)	30	0-175
Total protein (g/l)	66	50-70
Albumin (g/l)	31	25-40
Glucose (mmol/l)	5.49	4.44-6.66
Total calcium (mmol/l)	2.44	2.0-2.63
Phosphorus (mmol/l)	1.07	0.97-1.94

PARAMETERS	VALUE ON D0	REFERENCE RANGE
Haematocrit (%)	38	27-51
Haemoglobin (g/l)	13.6	9.7-17.2
Red blood cells (10 ¹² /l)	10.44	6.1-12
MCV (fl)	36.4	31.4-52.5
MCH (pg)	13	11.4-17.2
MCHC (g/l)	35.8	30.8-39.5
Reticulocytes (x10 ⁹ /l)	1.61	0.15-1.06
Platelets (x10 ⁹ /l)	170	180-555
Leucocytes (x10 ⁹ /l)	12.6	3.5-25
Neutrophils (x10 ⁹ /l)	9.66	11.8-12.11
Eosinophils (x10 ⁹ /l)	0.34	0.15-1.9
Basophils (x10 ⁹ /l)	0.01	0-0.1
Lymphocytes (x10 ⁹ /l)	2.18	1.1-10.85
Monocytes(x10 ⁹ /l)	3.9	0.69-1.18
Other cells (x10 ⁹ /l)	x	x

Discussion and conclusion

Balzac's two-month follow-up showed that Feline UR S1/Ox Urinary was very effective in preventing a recurrence of calcium oxalate calculi.

The owners were pleased with their cat's management and progress after two months. They reported good dietary compliance and palatability throughout the follow-up period. They planned to continue the diet in the medium to long term depending on further progress.

As the investigator, I felt that progress was very pleasing at the two-month follow-up. The presence of echogenic particles in suspension is not abnormal in the cat and in my view is independent of the context of cystotomy and calculus disease. This conclusion is supported by the absence of crystal-luria or signs of urinary tract inflammation. The microscopic haematuria indicated by the urine test strip is probably due to the method of sample collection (cystocentesis). The diet did not induce any biochemical or haematological changes.

It might be useful to have a longer-term follow-up (6 to 12 months).